

# Plaque Modification of the Common Femoral Artery: A Novel Endovascular Approach

*Raghotham Patlola, MD<sup>1</sup>, Chris Hebert, RT<sup>1</sup>, Angostino Ingraldi, M.D.<sup>1</sup>, Michael McElderry, M.D<sup>1</sup>. David Allie, MD<sup>2</sup>*

*1 - Cardiovascular Institute of the South, Lafayette, LA*

*2 - Louisiana Cardiovascular and Limb Salvage Center*

# Background

- Treatment of the Common Femoral Artery has historically been very difficult due to high dissection rates and the risks of having to stent across the origins of the Profunda or Superficial Femoral Artery. Patients treated with the CSI Diamondback Orbital Atherectomy device and adjunctive low pressure balloon inflation was performed to evaluate efficacy.

# Methods

- From October 1, 2008 – February 28, 2009, 14 patients with significant stenosis of the Common Femoral Artery were treated using the Diamondback Orbital Atherectomy catheter and adjunctive low pressure PTA if needed. Crown sizes used ranged from 2.0 mm- 2.25 mm.

# Results

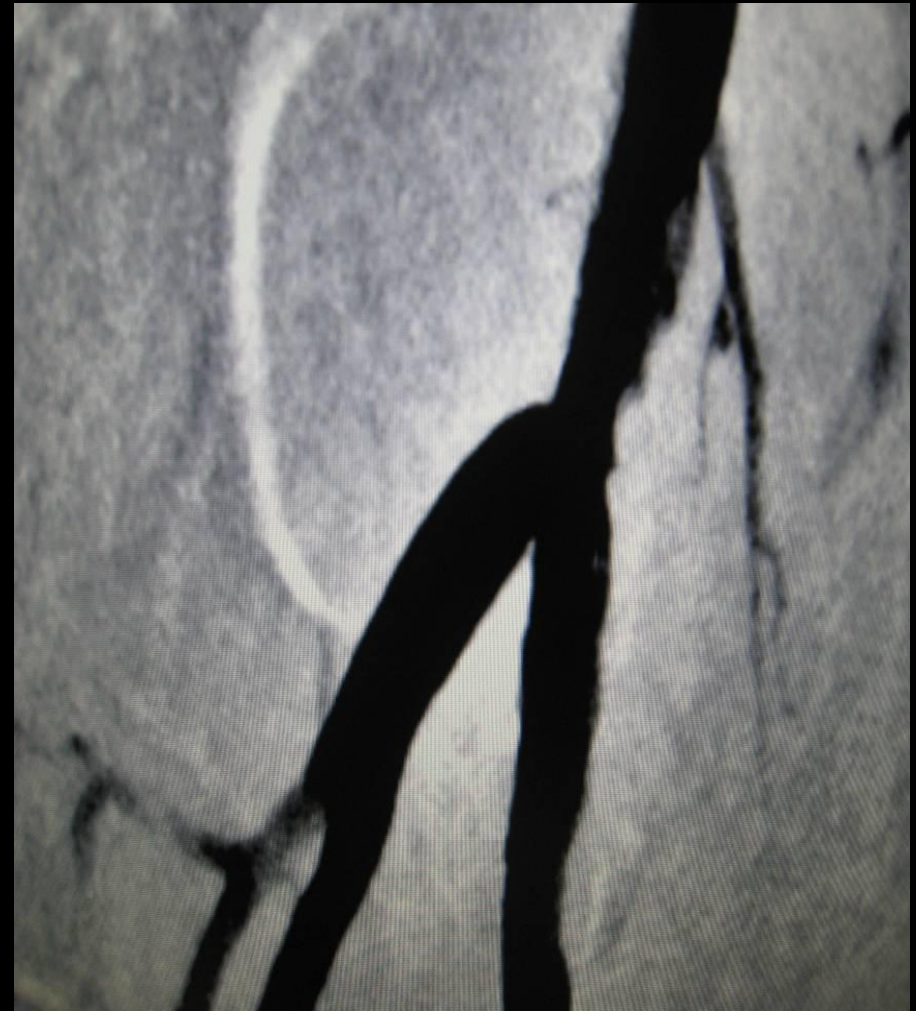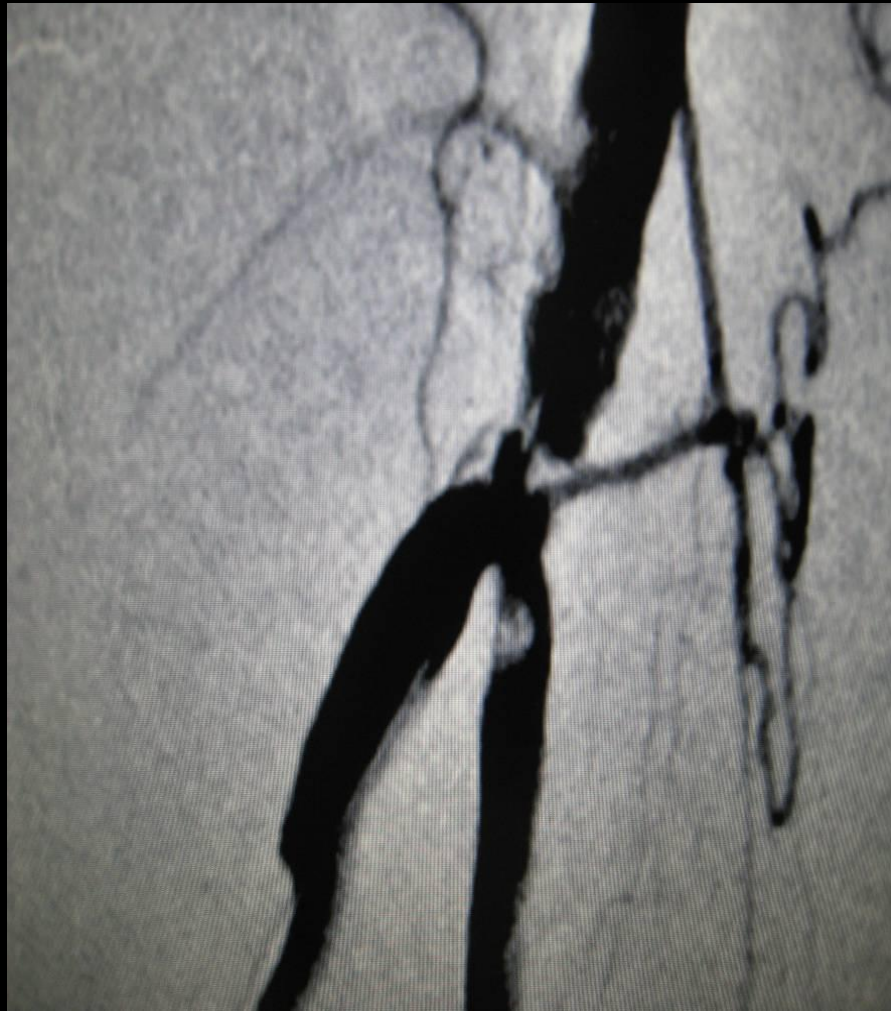
- The procedural success rate was 100%. Average vessel size was 6.3 mm. Crown diameters used for treatment were 2.0mm 12/14 (85%) and 2.25mm 2/14 ( 15%). 1/14 (7%) lesions required no further therapy and were considered a stand alone result. Of the remaining 15 patients, low pressure/long dilation time inflations were performed. The average pressure was 3 atmospheres for an average inflation time of 3 minutes. Average lumen size by visual estimation following treatment was 5.8mm. 2/14 (14%) were noted to have small areas of dissection that were felt to be non flow limiting. There were 0/16 (0%) lesions which required stenting. No perforations or other major complications were noted.

# Conclusion

- Plaque modification utilizing the Diamondback Orbital atherectomy device combined with low pressure/long inflation times is safe and effective for the treatment of Common Femoral Artery disease. Further data is needed for long term durability.

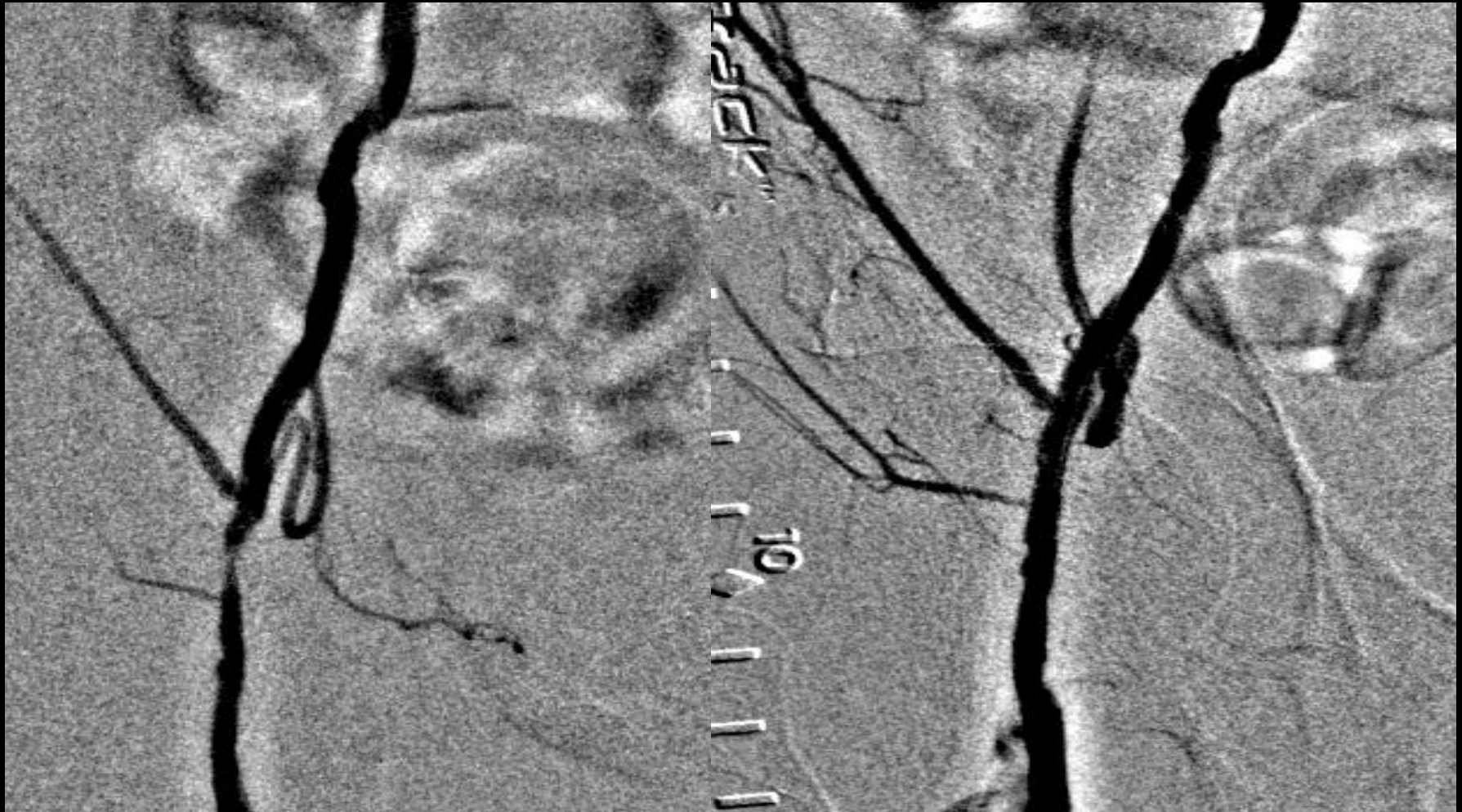# Heavily Calcified Common Femoral

Treated with a 1.75 Classic and a 2.25 Solid 70g for total treatment time of 5:45. 6x4 balloon at 3 atm for excellent result.



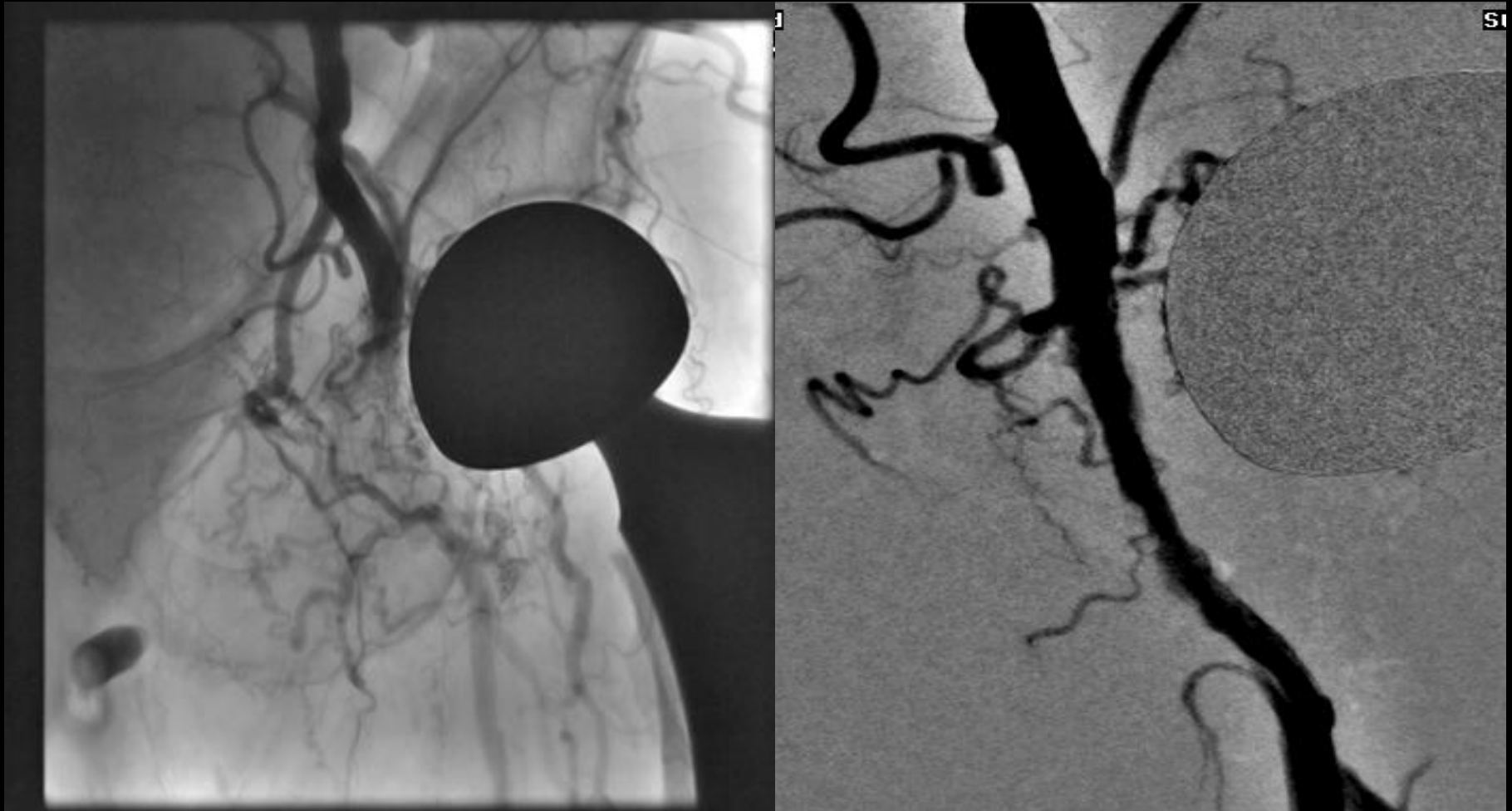# Denovo CFA Stenosis

Treated with a 2.0 Classic Crown for total treatment time of 1:30. No Adjunctive Therapy.



# Common Femoral CTO

Treated with a 2.0 Classic Crown for total treatment time of 2:15. 5x4 balloon at 2 atm.



# Common Femoral CTO

Treated with a 2.0 Classic Crown for total treatment time of 1:50. 6x6 balloon at 3 atm.

